


Classification of Newborn Ear Malformations and their Treatment with the EarWell Infant Ear Correction System

Lily N. Daniali, M.D.
 Kameron Rezzadeh, M.D.
 Cheryl Shell, A.P.N.
 Matthew Trovato, M.D.
 Richard Ha, M.D.
 H. Steve Byrd, M.D.

Dallas, Texas



Background: A single practice’s treatment protocol and outcomes following molding therapy on newborn ear deformations and malformations with the EarWell Infant Ear Correction System were reviewed. A classification system for grading the severity of constricted ear malformations was created on the basis of anatomical findings.

Methods: A retrospective chart/photograph review of a consecutive series of infants treated with the EarWell System from 2011 to 2014 was undertaken. The infants were placed in either deformation or malformation groups. Three classes of malformation were identified. Data regarding treatment induction, duration of treatment, and quality of outcome were collected for all study patients.

Results: One hundred seventy-five infant ear malformations and 303 infant ear deformities were treated with the EarWell System. The average age at initiation of treatment was 12 days; the mean duration of treatment was 37 days. An average of six office visits was required. Treated malformations included constricted ears [172 ears (98 percent)] and cryptotia [three ears (2 percent)]. Cup ear (34 ears) was considered a constricted malformation, in contrast to the prominent ear deformity. Constricted ears were assigned to one of three classes, with each subsequent class indicating increasing severity: class I, 77 ears (45 percent); class II, 81 ears (47 percent); and class III, 14 ears (8 percent). Molding therapy with the EarWell System reduced the severity by an average of 1.2 points ($p < 0.01$). Complications included minor superficial excoriations and abrasions.

Conclusion: The EarWell System was shown to be effective in eliminating or reducing the need for surgery in all but the most severe malformations. (*Plast. Reconstr. Surg.* 139: 681, 2017.)

CLINICAL QUESTION/LEVEL OF EVIDENCE: Therapeutic, IV.

Ear molding in the neonatal period offers a window of opportunity for correcting auricular deformities and malformations without surgery and long before the onset of peer teasing, bullying, and loss of self-esteem. Taking advantage of the temporary malleability of the infant ear cartilage, the EarWell Infant Ear Correction System (Becon Medical Ltd., Naperville, Ill.) can apply a combination of anterior and posterior forces that selectively shape and expand targeted areas, including the helical rim, scapha, antihelix, superior crus, concha, and lobule. By intervening during the newborn period, the psychosocial morbidity, pain, and costs of surgical correction are avoided.¹⁻³ With 15 to 20 percent of newborns presenting with misshapen

ears that do not self-correct, ear molding techniques provide tremendous potential benefit to the lives of many children.⁴

Disclosure: Dr. Byrd has a royalty agreement with Becon Medical for his work designing the EarWell device. Dr. Ha has financial investment in Becon Medical. None of the other authors have any other financial disclosures that might pose or create a conflict of interest with information presented in this article. No funding was received for the work presented in this article.

Supplemental digital content is available for this article. Direct URL citations appear in the text; simply type the URL address into any Web browser to access this content. Clickable links to the material are provided in the HTML text of this article on the Journal’s website (www.PRSJournal.com).

From Pediatric Plastic Surgery Institute.
 Received for publication April 4, 2016; accepted September 1, 2016.
 Copyright © 2017 by the American Society of Plastic Surgeons
 DOI: 10.1097/PRS.00000000000003150

Downloaded from https://journals.lww.com/plasrecon by KCLMqWQJESAMCQJ9F-3947TCUCQJASLXKmeNMW/+4QDZITTDILUJONOC7A5IIPPHZV7NWXK7966OMgRkqD9axxHEX540MEBY/CHK on 07/23/2019

Ear anomalies are classified into two major categories: deformation or malformation. Although deformations are characterized by a misshapen but fully developed pinna with no missing skin or cartilage, malformations demonstrate a partial absence of skin and/or cartilage resulting in an underdeveloped pinna from an error in embryologic development.^{4,5} Review of the plastic surgery literature demonstrates the efficacy of neonatal ear molding in the correction of deformational ear anomalies. Currently, there are no large studies focused on evaluating its application to the malformed ear, specifically, the constricted ear.^{4,6-9} Some small, all-inclusive studies have shown limited success in treating mildly constricted ears but have had failure to resolve or improve moderate and severe constrictions. As a result, it is generally asserted that the constricted ear malformation requires surgery and infant ear molding is ineffective and should not be attempted.¹⁰ As our experience with the use of the EarWell System increased, we began offering molding therapy to all patients with constricted malformations despite the severity. This article presents a single practice's experience treating a consecutive series of infants with deformational and malformational ear anomalies with the EarWell Infant Ear Correction System. Our large series provides a unique opportunity to evaluate the efficacy and outcomes of the EarWell System when treating newborn ear malformations.

PATIENTS AND METHODS

Treatment Course

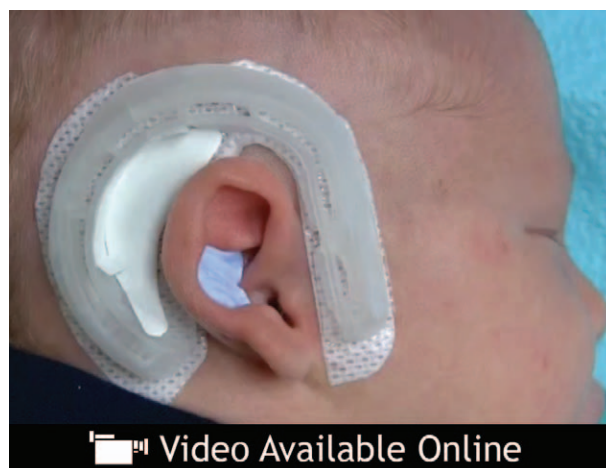During the initial consultation, the type of auricular deformation or malformation was diagnosed, and clinical photographic documentation was obtained. If the ears were amenable to molding, the benefits, risks, and alternatives were discussed in detail with the parents. In the cases where the newborn was older than 3 weeks and not premature, parents were advised that molding failure could be as high as 50 percent, and a special consent acknowledging their acceptance was required. Experience with premature infants has shown that the age for effective molding may be extended by the number of weeks of prematurity.

A "Hot Topic Video" by Editor-in-Chief Rod J. Rohrich, M.D., accompanies this article. Go to PRSJJournal.com and click on "Plastic Surgery Hot Topics" in the "Digital Media" tab to watch. On the iPad, tap on the Hot Topics icon.

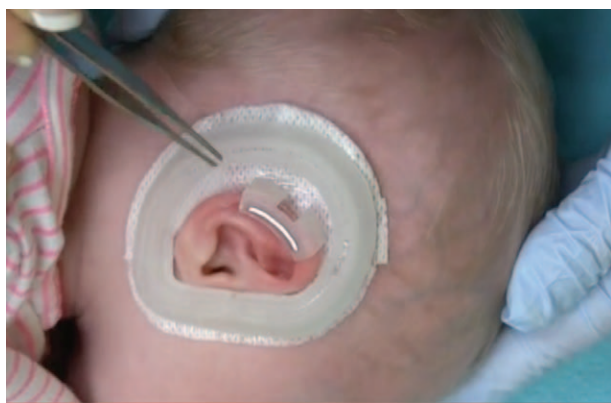Once informed consent was obtained, ear molding typically was initiated during the first visit.

Newborns with deformities were scheduled for follow-up visits in 2 weeks with the anticipation of a device change. Newborns with malformations were scheduled for weekly follow-up visits to monitor progress and to both customize and modify the EarWell device, as more aggressive molding techniques were used in these instances. In all cases, the device baseplate was replaced if the adhesive had loosened.

For molding of malformations such as constricted ears, advanced molding techniques were used to counteract the significant resistive forces to expansion resulting from tissue deficiency. (See **Video, Supplemental Digital Content 1**, which describes treatment of malformations such as constricted ears using advanced molding techniques to counteract significant resistive forces to expansion resulting from tissue deficiency, available in the "Related Videos" section of the full-text article on PRSJJournal.com or, for Ovid users, at <http://links.lww.com/PRS/C67>. See **Video, Supplemental Digital Content 2**, which details application of the EarWell device, available in the "Related Videos" section of the full-text article on PRSJJournal.com or, for Ovid users, at <http://links.lww.com/PRS/C68>.) These techniques included the addition of multiple retractors that were sequentially advanced to maximize auricular expansion. Medical grade cyanomethacrylate adhesive was frequently used to anchor retractors to the helical rim at the junction with the scapha and to advance the rim laterally. Brown



Video 1. Supplemental Digital Content 1, which describes treatment of malformations such as constricted ears using advanced molding techniques to counteract significant resistive forces to expansion resulting from tissue deficiency, is available in the "Related Videos" section of the full-text article on PRSJJournal.com or, for Ovid users, at <http://links.lww.com/PRS/C67>.



 Video Available Online

Video 2. Supplemental Digital Content 2, which details application of the EarWell device, is available in the “Related Videos” section of the full-text article on PRSJJournal.com or, for Ovid users, at <http://links.lww.com/PRS/C68>.

Micropore tape (3M, St. Paul, Minn.) anchored to the rim and attached to the inner EarWell adhesive would be used to roll out the helical rim when needed. Silicone molding material was occasionally added along the inner surface of the helical rim to extend shaping over the posterior former. Occasionally, when a high conchal crus was present, silicone material was used to customize the base of the conchal former. Similarly, in constricted cup ear malformations presenting with a constriction of the inner antihelical ring of cartilage, the sidewall of the conchal former was augmented with silicone to progressively expand the constrictive ring surrounding the concha. In addition, progressive pressure was applied to the conchal former through the addition of foam between the conchal former and the anterior lid of the EarWell. These specific maneuvers were used to decrease the concha mastoid angle. Finally, when these more aggressive techniques were implemented, the newborn was monitored more closely for development of skin irritation or abrasion. If irritation was seen, the retractor or conchal former was either repositioned or removed until the irritation resolved.

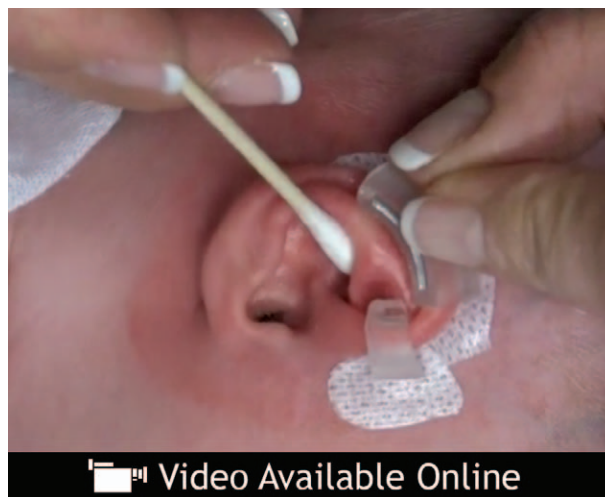Depending on the severity of the auricular anomaly, molding with the full device (the baseplate, retractors, conchal conformer, and anterior cradle) would typically reach completion after 4 weeks of treatment. After the desired shape was attained, retention taping for an additional 2 weeks was used if the deformity was severe or a malformation was present. The technique of retention taping was accomplished by affixing a retractor to the helical rim in the area of prior deformity and attaching it to a double-sided tape affixed to

the retroauricular skin. The double-sided tape not only secured the retractor but also served as a barrier between the base of the retractor and the retroauricular skin, thereby minimizing abrasion or excoriation of the skin. The retractor was then further secured in place with brown Micropore tape. Parents were instructed on how to reinforce and replace this tape as needed.

A modified technique is required for the correction of cryptotia. (See **Video, Supplemental Digital Content 3**, which describes the diagnosis of cryptotia and treatment strategies, available in the “Related Videos” section of the full-text article on PRSJJournal.com or, for Ovid users, at <http://links.lww.com/PRS/C69>.) Before the application of the EarWell device, the pinna is pulled out of its “buried” position by attaching a retractor to the helical rim and advancing the rim and entire pinna onto a double-surface “bottom tape” that is attached to the shaved cranial scalp. The ear is retained in this position for 7 to 10 days after which the standard EarWell device is applied and shaping completed.

Study Design

A retrospective review of a consecutive series of infants treated with the EarWell System at a single pediatric plastic surgery practice from 2011 to 2014 was performed. Demographic and clinical data collected included age, adjusted age at the time of initiating treatment, gestational age, medical comorbidities, type of pretreatment deformity or malformation, duration of treatment, number of visits, and date of last follow-up. Types of deformity were categorized as follows: prominent,



 Video Available Online

Video 3. Supplemental Digital Content 3, which describes the diagnosis of cryptotia and treatment strategies, is available in the “Related Videos” section of the full-text article on PRSJJournal.com or, for Ovid users, at <http://links.lww.com/PRS/C69>.

lidding, conchal crus, Stahl, and helical rim deformities (i.e., compressed, irregular, no rim). The types of malformations were categorized as constricted ears and cryptotia. Cup ear was considered a variety of the constricted ear.

For each study patient, pretreatment and post-treatment clinical photographs were evaluated by two blinded plastic surgeons. The two surgeon reviewers independently evaluated the quality of correction of all diagnosed deformities and malformations by comparing pretreatment and post-treatment images. If the two surgeons disagreed, a third, blinded and independent plastic surgeon was consulted. The posttreatment outcome was graded as excellent, good, fair, or poor based on predetermined definitions provided to the reviewers (Table 1). Infants without a complete set of pretreatment and posttreatment clinical photographs were excluded from the study (23 ears in 22 patients). In addition, six ears with a Darwin tubercle were excluded, as ear molding is not offered for this nonmoldable defect caused by an outgrowth of excess cartilage. Finally, data were collected on the incidence of complications during the treatment course, such as skin excoriations, allergic reaction, and infection. An infection was defined as clinical examination findings suggestive of infection for which a course of antibiotics was prescribed.

Constricted Ears

To both clearly assess the pretreatment severity of constriction and measure posttreatment outcomes, we developed a new classification system to define the constricted ear (Fig. 1). The classification system consists of three classes of increasing severity, each characterized by progressive changes in the auricular longitudinal axis, superior crus, scapha, prominence, and degree of helical and antihelical constriction. Of note, the system defines a class I constriction as mild helical hooding caused by a mild deficit of skin and cartilage. By comparison, helical hooding without a deficit of skin and cartilage is a deformational lidding, not a constriction. The presence of

constriction around the helical rim and within the antihelix is an important marker of increasing tissue deficiency. The “purse-string effect” of these constrictive rings produces the classic “cup ear.” The cup ear malformation is thus distinguished from the prominent ear deformity by the presence of these two constrictive cartilaginous rings, and in this classification system, it is recognized as a marker of increasing severity.

Using the classification system, all constricted ears were assigned a pretreatment and posttreatment severity class by the two independent and blinded reviewers. Finally, the posttreatment outcome was graded as excellent, good, fair, or poor based on predetermined definitions provided to the reviewers (Table 1). An interrater agreement score was calculated to assess the level of agreement between the reviewers.

RESULTS

Three hundred three newborn ear deformities (111 patients) and 175 infant ear malformations (90 patients) were treated with the EarWell System. The mean age for initiation of ear molding with the EarWell was 12.5 days, with the average adjusted gestational age at initiation of treatment at 39.2 weeks. The mean duration of treatment was 37 days (range, 12 to 109 days), with no significant difference between length of treatment for deformational versus malformational ear anomalies. Retention taping was used in 66 percent of patients for a mean of 1.8 weeks. Patients, on average, required six office visits to complete the course of treatment, but there was a large range, with some infants requiring as few as three office visits to a maximum of 13 visits to complete treatment.

Deformational Anomalies

Treated deformities included conchal crus [80 ears (26.4 percent)], helical rim abnormalities [75 ears (24.8 percent)], Stahl ear [63 ears (20.8 percent)], lidding [58 ears (19 percent)], and prominent ear [27 ears (9 percent)]

Table 1. Posttreatment Photographic Grading for Deformational and Malformational (Constricted) Ear Anomalies

Grade	Shape	Deformation/Malformation
Excellent	Normal ear shape	No appearance of original deformation/malformation
Good	Nearly normal ear shape	Mild yet nondistracting retention of original deformation/malformation
Fair	Improved but not a normal ear shape	Noticeable, distracting retention of original deformation/malformation
Poor	No improvement	Abnormal ear shape with retention of original deformation/malformation










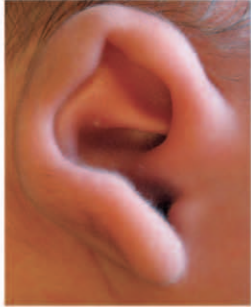


	Longitudinal Axis	Superior Crus	Helical Hooding	Scapha	Prominence
Class I	Shortened	Flattened	Mild skin & cartilage deficit Mild resisting forces	Present	Mild
					
Class II	Shortened	Absent	Moderate skin & cartilage deficit Moderate resisting forces	Shortened, decreased definition	Increased
					
Class III	Severe shortening	Absent	Severe skin & cartilage deficit Severe resisting forces	Complete obliteration	Severe
					

Fig. 1. Classification system for the grading of constricted ear malformation severity.

(Fig. 2). One hundred two ears (33.7 percent) presented with more than one identifiable deformity. By independent, blinded photographic review comparing premolding and postmolding images, complete correction, defined as no identifiable deformity, was achieved in 90.2 percent of conchal crus, 86 percent of helical rim, 85 percent of Stahl, 80.4 percent of prominent,

and 92 percent of lidded ears (Table 2). After molding with the EarWell System, 95.1 percent of conchal crus deformities, 97.5 percent of helical rim deformities, 97 percent of Stahl ears, 93.2 percent of lidded ears, and 88 percent of prominent ears were graded as having attained an excellent to good outcome after molding with the EarWell System.

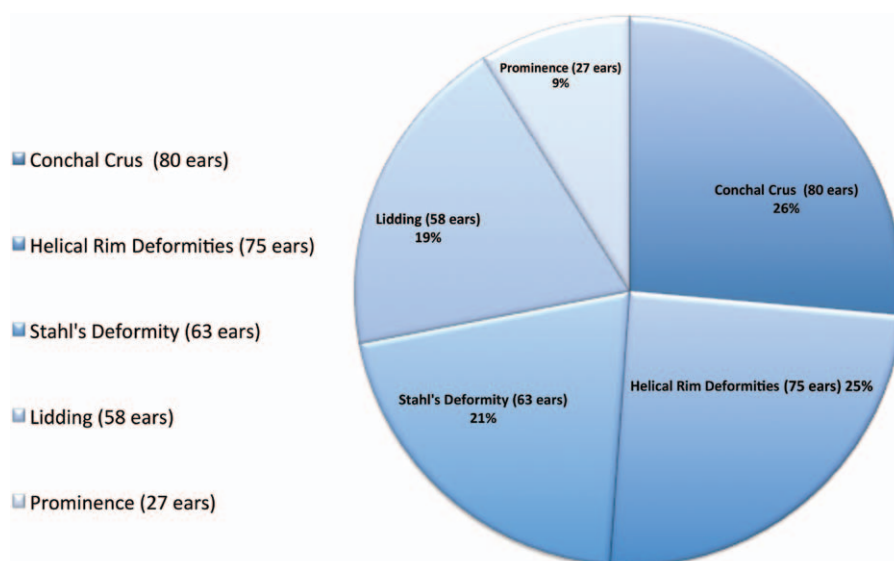


Fig. 2. Distribution of deformational ear anomalies treated with the EarWell System (303 ears).

Table 2. Posttreatment Outcomes*

	Complete Correction (%)	Residual Deformity (%)	Excellent (%)	Good (%)	Fair (%)	Poor (%)
Lidding	92	8	84.7	8.5	6.8	0
Conchal crus	90.2	9.8	75.6	19.5	4.9	0
Helical rim	86	14	71	26.5	2.5	0
Stahl	85	15	77	20	3	0
Prominence	80.4	19.6	61	19.7	19.7	0
Darwin tubercle	50	50	50	0	50	0

*Percentage of deformities completely corrected vs. percentage still with appreciable residual deformity with qualitative outcome grading.

Of note, of the 303 ear deformities treated from 111 patients (212 ears), 91 ears (43 percent) had mixed deformities, defined as having more than one identifiable deformational anomaly. The clinical photographic grading results were stratified by ears treated with only one deformation versus multiple identified deformations, regardless of the type of deformation. Ears with only one deformation had an excellent to good outcome in 97 percent and a fair outcome in 3 percent. Ears with mixed deformities had excellent to good outcomes in 88 percent and fair outcomes in 12 percent.

Malformational Anomalies

Treated malformations included cryptotia [3 ears (1.7 percent)] and constriction [172 ears (98.3 percent)]. All the cryptotia ears were corrected completely and graded as having excellent posttreatment photographic outcomes. Using the constriction classification system, the reviews assigned pretreatment severity classes to the

constricted ears: 77 class I ears, 81 class II ears, and 14 class III ears. [See Figure, Supplemental Digital Content 4, which shows the distribution of constricted ear malformations by pretreatment constriction severity class (172 ears), <http://links.lww.com/PRS/C70>.] Grading of posttreatment photographs demonstrated significant decreases in constriction class severity (Table 3). Constriction was significantly improved as evidenced by a reduction in constriction severity class by, on average, 1.24 points ($p < 0.01$). Overall posttreatment outcomes were graded as excellent to good in 88.2 percent, fair in 11 percent, and poor in 0.8 percent of constricted ears, with 96.7 percent interrater reliability. Premolding and postmolding photographs of each constriction severity class have been selected to demonstrate typical treatment outcomes (Figs. 3 and 4). [See Figure, Supplemental Digital Content 5, which shows the cases of class I constricted ears before (left) and after (right) molding treatment, <http://links.lww.com/PRS/C71>.]

Table 3. Pretreatment and Posttreatment Constriction Class Severity*

	No. of Ears		Average Decrease in Constriction Class Severity	<i>p</i>
	Pretreatment (%)	Posttreatment (%)		
No constriction	—	88 (69)		
Class I	45 (35)	24 (19)	0.93	<0.04
Class II	69 (53)	12 (9.4)	1.52	<0.05
Class III	13 (10)	3 (2.3)	1.4	<0.06
All constricted ears			1.3	<0.01

*Total, 172 ears.

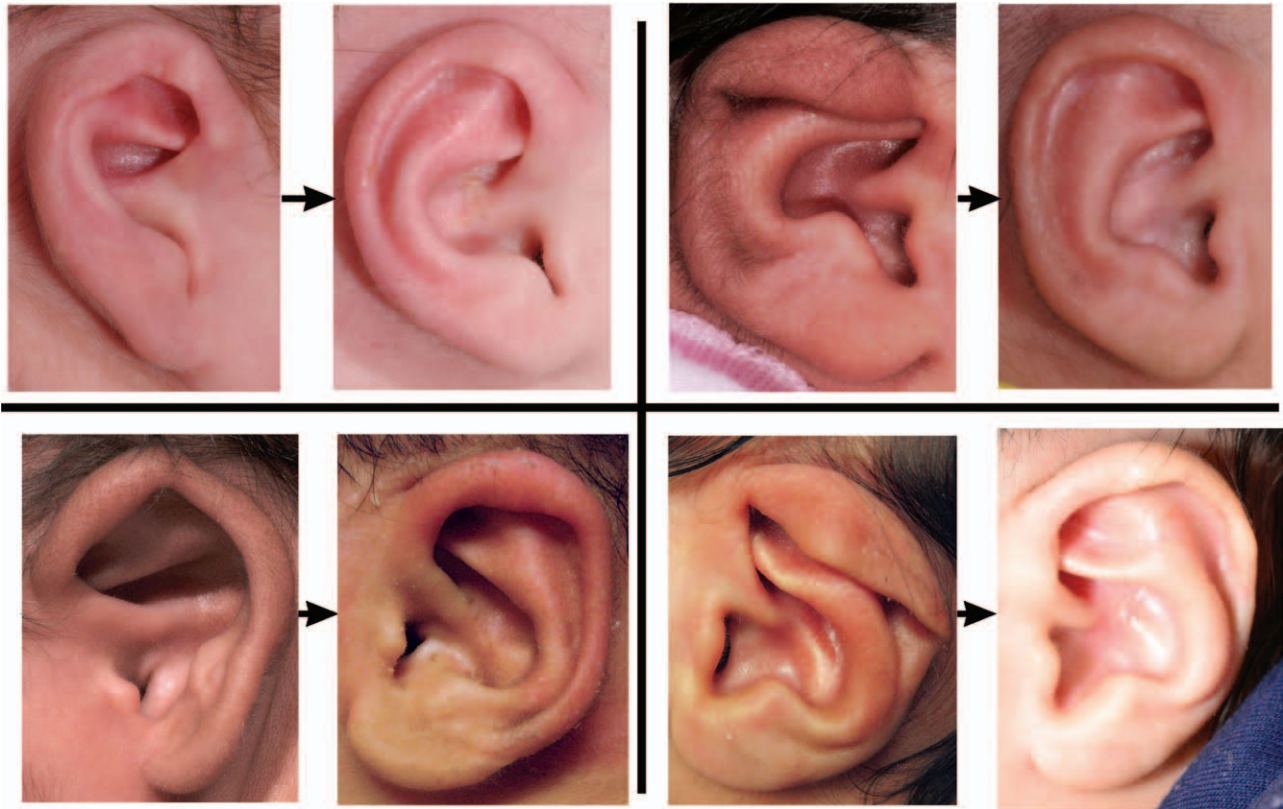


Fig. 3. Cases of class II constricted ears before (left) and after (right) molding treatment.

Complications

Complications consisted primarily of minor superficial excoriations in 36 ears (22 deformational ear anomalies and 14 constricted ears), with an overall 7.6 percent rate of incidence for the entire series of treated newborns (7.2 percent incidence for deformational versus 8.1 percent for constricted ears). Of these excoriations, 97.8 percent healed after temporarily suspending helical rim retractor expansion for 5 to 7 days. (See **Figure, Supplemental Digital Content 6**, which shows that superficial excoriations from the helical rim retractor were the most common complication. Approximately 98 resolved with temporary suspension of helical rim expansion for 5 to 7 days, <http://links.lww.com/PRS/C72>.) It is important to

note that infants treated for malformations were seen weekly (twice as frequently) to both advance the treatment but also to monitor for abrasion or irritation from the increased pressure and tension being applied. We believe this protective measure has been effective as demonstrated by the nearly equal incidence of complications between the two groups. Eight ears developed an allergic reaction to the device adhesive requiring early termination of ear molding, and one ear developed an infection.

DISCUSSION

This study presents the largest series of newborns with auricular deformations and malformations undergoing ear molding with the EarWell

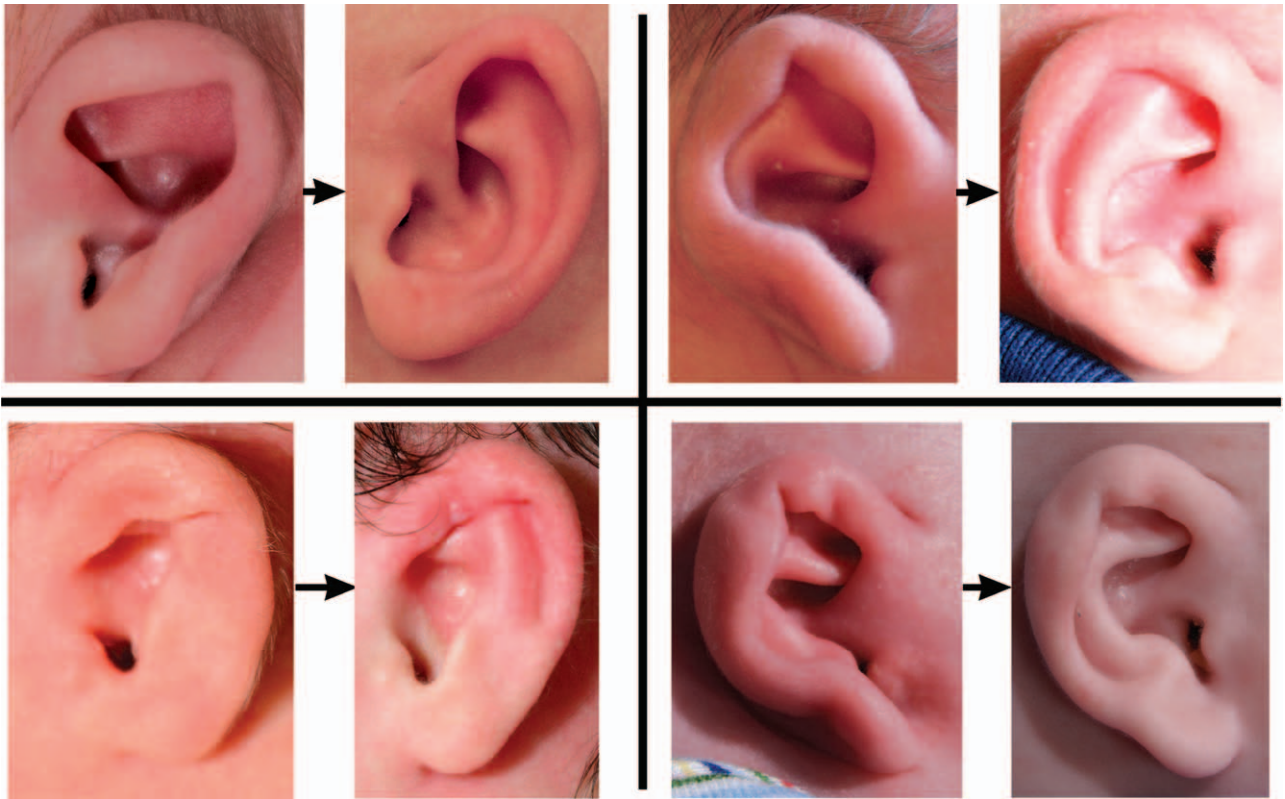


Fig. 4. Cases of class III constricted ears before (*left*) and after (*right*) molding treatment.

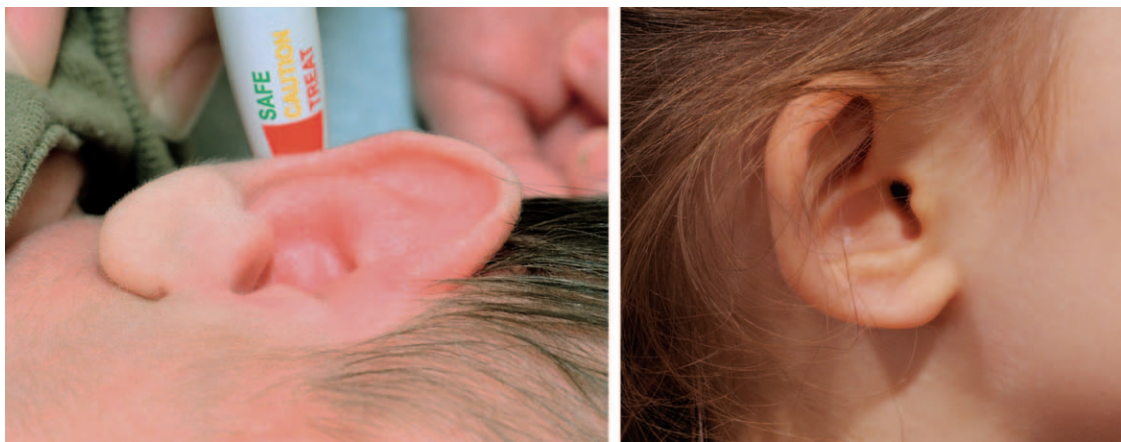

Fig. 5. Use of a projectometer for diagnosis of prominent ear. (*Left*) Newborn with prominent ear. (*Right*) Lateral view of the same patient at maturity. Newborn projection has tripled at maturity.

Infant Ear Correction System, using a standardized treatment protocol, and with photographic documentation for outcomes assessment. Although our experience with molding newborn ears dates back to the late 1980s, the EarWell Infant Ear Correction System has been our preferred method of treatment for the past 6 years. Our experience has taught us that the early initiation of treatment is advantageous with all molding techniques. The opportunity for early treatment can be hampered

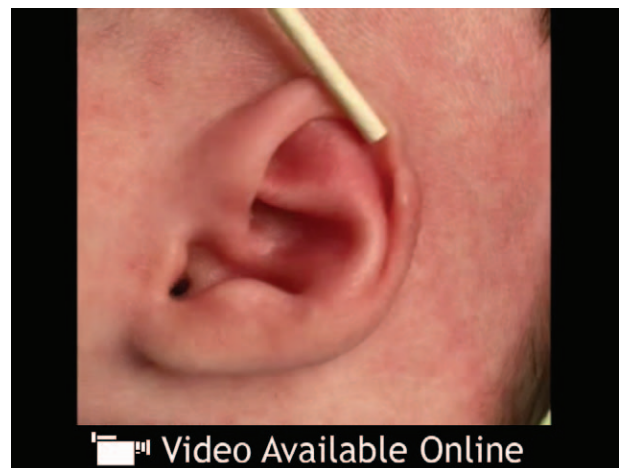by a failure to convince pediatricians that the majority of misshapen newborn ears do not self-correct, and that watchful waiting effectively eliminates the opportunity for nonsurgical correction. Furthermore, no self-correction was seen among newborn infants with malformed ears, defined as ears with missing skin and cartilage.

The results of the deformational anomalies treated in this series are consistent with the current body of literature. Ear molding with the

EarWell System provides consistently efficacious results in correcting lidding, conchal crus, helical rim, prominence, and Stahl deformities, with high rates of good to excellent qualitative outcomes. Ear molding treatment had nearly complete correction of all effaced antihelical folds. Of all the deformities treated, the prominent ear had the greatest number of ears with retained residual deformity (19.6 percent). Nevertheless, 88 percent of the treated prominent ears had an excellent to good outcome. The newborns with residual deformity typically are associated with a history of autosomal dominant genetics for ear prominence running through each generation of their family. That being said, we were unable to differentiate those who would have a stable complete correction versus those who would have relapse with residual deformity. In addition, it is important to point out a significant decrease in the number of prominent ear deformities treated in this consecutive series of newborns than reported in previously published nursery study data by the same senior author (H.S.B), 9 percent versus 45 percent. This change is directly attributable to two factors: (1) a failure to distinguish between some cup ear malformations and prominent deformities in the nursery study and (2) a propensity among referring pediatricians to completely overlook the prominent ear deformity. This bias in diagnosis is completely understandable because the infant cup ear stands out as abnormal to both parent and physician, whereas the prominent ear deformity “flies under the radar,” generally requiring direct measurement for diagnosis. The normal projection of the newborn ear is 5 to 7 mm. Borderline projection ranges from 7 to 10 mm, whereas ears projecting over 10 mm are clearly abnormal. With growth to adulthood, there is roughly a three-fold increase in the projection of a newborn infant ear. It cannot be stressed enough that the diagnosis of prominent ear is often subtle and requires direct measurement of ear projection from the cranial skin to the midpoint of the helical rim with a ruler or projectometer (Fig. 5).

The data comparing the clinical outcomes of ears with a single deformity to ears with multiple identifiable deformities warrant attention. Ears with mixed deformities had a higher rate of fair photographic outcomes (3 percent versus 12 percent, respectively). Although the overall results demonstrate that ears with multiple identifiable deformational anomalies can be effectively treated with ear molding techniques, it is important to counsel families that the posttreatment outcome may be negatively impacted by compounding deformations.

Historically, the constricted ear has had a multitude of imprecise descriptors, such as lop, cup, lidding, and many others. Often, there is an intermixing of deformational and malformational adjectives that further obfuscates. To accurately measure outcomes in a study about the treatment of constricted ears, it was essential that our definition of the constricted ear be precise and unambiguous. A malformation must have missing tissue, and even the mildest constriction, by definition, must demonstrate a tissue deficit to be classified as constricted ear. For this reason, we chose to use a new classification system as an alternative to the Tanzer classification system because the Tanzer I constricted ear describes a lidding deformation, not a constriction malformation.¹¹ In contrast, the class I constriction as defined in this study clearly must have a demonstrable deficit of skin and cartilage. We perform a simple diagnostic test during the clinical examination to differentiate between a lidding deformation and a class I constriction. (See **Video, Supplemental Digital Content 7**, which describes how to distinguish between lidding and constriction, available in the “Related Videos” section of the full-text article on PRSJournals.com or, for Ovid users, at <http://links.lww.com/PRS/C73>.) With a cotton-tip applicator placed under the area of helical hooding, there should be no resistance in elevating the helical rim and shaping the superior crus to produce a normal appearing ear. If the hooding cannot be lifted with the cotton-tip applicator, the auricle is at a minimum a class I constriction. The result of this clinical test is documented in each patient’s initial examination, and it provided the basis of



Video 4. Supplemental Digital Content 7, which describes how to distinguish between lidding and constriction, is available in the “Related Videos” section of the full-text article on PRSJournals.com or, for Ovid users, at <http://links.lww.com/PRS/C73>.

how infants were accurately diagnosed with the correct anomaly.

Successful correction of the constricted ear depends on expanding an auricle that is deficient of tissue. (See **Figure, Supplemental Digital Content 8**, which shows an example of auricular expansion during ear molding treatment demonstrated by consecutive photographs of a newborn with bilateral class I constricted ears, <http://links.lww.com/PRS/C74>.) Helical rim retractors exert gentle, sustained force on the auricular tissue, resulting in helical rim tissue expansion and longitudinal auricular lengthening. Biological creep is a core plastic surgery principle; when tissue is chronically stretched, stretch-induced signal transduction pathways lead to an increased production of collagen, epidermal proliferation, fibroblast mitosis, and angiogenesis. Expansion of auricular cartilage, a tissue with much higher resistance than skin, requires directed and sustained force to stimulate the tissue expansion necessary to achieve good to excellent results in the majority of class I and II constrictions. To correct a constricted ear malformation, helical tissue expansion and a decrease in conchal projection is necessary. The EarWell device uses the posterior shell or base plate as the foundation for the anterior and laterally directed forces generated by the retractors and conchal conformer, respectively. The base plate also serves as a foundation for the placement of silicone molding material to customize the final shaping. Alternative molding systems that only bend the ear cartilage back along the antihelix fail to produce the vectors and forces

needed to truly expand the tissue deficiency of a constricted ear.

With increasing severity into class II and III constriction, many constricted ears present with a second inner ring of constriction along the antihelix. This “purse-string” of the cartilage is antihelical cartilage tissue deficiency (Fig. 6). This inner ring of constriction causes the inferior limb of the triangular fossa, the antihelix, the antitragus, and the lobule to bow forward, increasing the auricle’s prominence and further narrowing and constricting the concha. The plastic surgery literature often refers to this phenotypic presentation of antihelical cartilage deficiency as “cup ear deformity.” In our opinion, it is a malformation secondary to its inherent tissue deficiency. In essence, this second ring of inner deficiency and conchal bowl constriction can block the posterior expansion of the concha, making correction of the constricted prominent ear (the cup ear) particularly problematic.

For the class III constricted ear, ear molding was unable to resolve all the elements of the constriction, but there were clear improvements in the auricular structure, such as increased definition of the scapha, decreased conchal bowl constriction, and increased longitudinal axis length, that transformed many grossly malformed ears to acceptable frameworks (Fig. 4). Despite the remaining elements of constriction, the natural contours of these molded ears remain superior to the contours of a surgically modified constricted ear. Finally, through molding, the class III constricted ears have had important modifications to

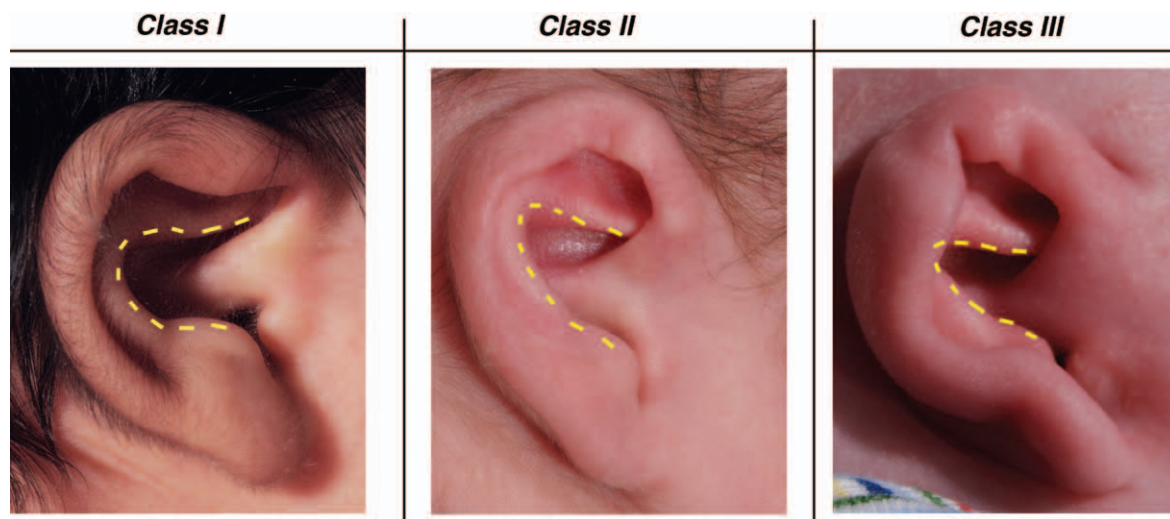


Fig. 6. Within the constricted ear malformation, there are newborns that present with a second, inner ring of antihelical constriction. Often described as a cup ear, the antihelical cartilage ring tightens like a purse-string around the concha, further increasing the conchal-mastoid angle.

the auricular framework that effectively “downgraded” the constriction severity, allowing for optimization of eventual surgical outcome.

Lastly, the effect of age at treatment initiation has been a persistent question from many providers. The importance of early recognition of ear anomalies cannot be overstated. We have made considerable efforts to educate referring pediatricians how to recognize and rapidly refer affected infants; thus, within the constricted ear treatment group, only five ears had treatment initiated beyond 3 weeks after birth. Although these five ears all achieved excellent to good photographic outcomes, we cannot endorse the efficacy of ear molding with late initiation of treatment with such a small subset of patients for outcome analysis, and we strongly advise, based on our experience, that reliably retained and consistent results are achieved with early initiation of treatment. The only cases when we agreed to initiate treatment late were cases when families insisted on attempting molding with the understanding we could not guarantee complete correction or that relapse would not occur. These concerns are based on the recognized loss of pliability and increased stiffness in infant cartilage after 6 to 8 weeks of age and on reduced outcomes from a previous study when treatment was initiated after 3 weeks.⁴

Limitations

Although the major limitation of this study is its retrospective study design, every attempt was taken to minimize review bias by blinding reviewers to each other and all clinical details. Furthermore, individuals with financial interest in the EarWell System were excluded from involvement in data collection, photographic grading, and data analysis. Finally, although all surgeons within this practice were trained in the technique of ear molding by the senior author (H.S.B), multiple practitioners invariably introduce some technical variability.

Future Directions

As the cohort of infants with constricted ears grows, future studies will evaluate long-term patient and family satisfaction, psychological well-being, and the need for future surgical intervention.

CONCLUSIONS

Just as the medical community has accepted nasoalveolar molding as a valuable intervention with the power to decrease the severity of malformation and optimize cleft surgery outcomes, newborn ear molding deserves similar recognition and acceptance. This study adds to the body of literature supporting the efficacy of newborn ear molding to correct this extremely common congenital anomaly. Ear molding with the EarWell System effectively corrects both deformational and malformational auricular anomalies. Mildly to moderately constricted ears are reliably corrected to a good to excellent result. In the case of severely constricted ears, this nonsurgical therapy is capable of “downgrading” the constriction severity to allow for easier surgical correction at a later date.

H. Steve Byrd, M.D.

Pediatric Plastic Surgery Institute
9101 North Central Expressway, Suite 600
Dallas, Texas 75231
byrd.plasticsurgery@gmail.com

REFERENCES

1. Bradbury ET, Hewison J, Timmons MJ. Psychological and social outcome of prominent ear correction in children. *Br J Plast Surg*. 1992;45:97–100.
2. Horlock N, Vögelin E, Bradbury ET, Grobbelaar AO, Gault DT. Psychosocial outcome of patients after ear reconstruction: A retrospective study of 62 patients. *Ann Plast Surg*. 2005;54:517–524.
3. Macgregor FC. Ear deformities: Social and psychological implications. *Clin Plast Surg*. 1978;5:347–350.
4. Byrd HS, Langevin CJ, Ghidoni LA. Ear molding in newborn infants with auricular deformities. *Plast Reconstr Surg*. 2010;126:1191–1200.
5. Tan ST, Abramson DL, MacDonald DM, Mulliken JB. Molding therapy for infants with deformational auricular anomalies. *Ann Plast Surg*. 1997;38:263–268.
6. Doft MA, Goodkind AB, Diamond S, DiPace JI, Kacker A, LaBruna AN. The newborn butterfly project: A shortened treatment protocol for ear molding. *Plast Reconstr Surg*. 2015;135:577e–583e.
7. van Wijk MP, Breugem CC, Kon M. Non-surgical correction of congenital deformities of the auricle: A systematic review of the literature. *J Plast Reconstr Aesthet Surg*. 2009;62:727–736.
8. van Wijk MP, Breugem CC, Kon M. A prospective study on non-surgical correction of protruding ears: The importance of early treatment. *J Plast Reconstr Aesthet Surg*. 2012;65:54–60.
9. Ullmann Y, Blazer S, Ramon Y, Blumenfeld I, Peled IJ. Early nonsurgical correction of congenital auricular deformities. *Plast Reconstr Surg*. 2002;109:907–913.
10. Porter CJ, Tan ST. Congenital auricular anomalies: Topographic anatomy, embryology, classification, and treatment strategies. *Plast Reconstr Surg*. 2005;115:1701–1712.
11. Tanzer RC. The constricted (cup and lop) ear. *Plast Reconstr Surg*. 1975;55:406–415.